Case Report

Bilateral Pheochromocytoma in a Young Female Complicated with Microangiopathic Hemolytic Anemia (MAHA): A Rare Case

Fiza Ismail, Hafsa Zahid, Afraz Ahmad, Muhammad Ahmad Rauf, Haroon Ayub

Evercare Hospital, Lahore, Pakistan

Abstract

Pheochromocytoma is a rare catecholamine-secreting tumor of adrenal medulla. It classically presents with hypertension, palpitation and diaphoresis. Although cardiovascular and metabolic complications are well recognized, hematological manifestation such as microangiopathic anemia (MAHA) is exceedingly rare.

In this case report, we describe a 26-year-old girl with one-year history of poorly controlled hypertension who presented with gastrointestinal symptoms and anemia. Peripheral blood smear demonstrated schistocytes consistent with MAHA. Initial evaluation excluded autoimmune and infectious etiologies. Imaging revealed bilateral adrenal mass. The biochemical testing showed markedly elevated urinary vanillymandelic acid(VMA) levels, confirming the diagnosis of bilateral pheochromocytoma(PCC). The patient was managed with alpha- and beta-adrenergic blockade resulting in stabilization of blood pressure and clinical status, and was referred for definitive surgical management.

This case highlights a rare and potentially life-threatening presentation of pheochromocytoma complicated by MAHA and acute kidney injury. Early consideration of pheochromocytoma in young patients with unexplained hypertension and hematological abnormalities is crucial to prevent diagnostic delay and associated morbidity.

Keywords: Pheochromocytoma, Hypertension, Acute kidney injury, Anemia, Hemolytic, Thrombotic Microangiopathies

How to cite this:

Ismail F, Zahid H, Ahmad A, Rauf MA, Ayub H. Bilateral Pheochromocytoma in a Young Female Complicated with Microangiopathic Hemolytic Anemia (MAHA): A Rare Case. J Health Advance Res Genom. 2026;1(1): 52-56

Corresponding Author: Dr. Fiza Ismail **Email:** fizaismail21@gmail.com

Received: 21-07-2026 **Revised:** 16-09-2026 **Accepted:** 04-11-2026

Introduction

Pheochromocytomas (PCC) are rare neuroendocrine cell tumors, with incidence of less than 0.1% cases of global population.[1] In nearly 80% of the case s PCC is located in adrenal medulla chromaffin cells.[2] Majority of pheochromocytoma are sporadic, while nearly 30% are associated with hereditary syndromes such as multiple endocrine neoplasia type 2 (MEN 2), von Hippel-lindau disease (VHL), neurofibromatosis type 1 (NF1), and familial paraganglioma syndrome.[3]

The clinical presentation depends on the production of epinephrine, norepinephrine, and dopamine.[2] Often presenting with a "classic triad" of headache, diaphoresis and palpitation, associated with hypertension.[1]

It is often underdiagnosed, due to non-specific nature of symptoms and lack of awareness.[4] Furthermore, the marked heterogeneity of PCC may result in misattribution to more common diseases, justifying the characterization of pheochromocytoma as "the great masquerader".[5]

The diagnosis of PCC typically involves measurement of urinary catacholamines including adrenaline and noradrenaline and their metabolites (metanephrine and normetanephrine) followed by computed tomography (CT) or magnetic resonance imaging (MRI) for localization.[6] In few cases PCC can present as multiorgan crisis,[7] rare clinical manifestations such as microangiopathic hemolytic anemia (MAHA) have been reported in association with pheochromocytoma, particularly in cases with malignant disease.[8]

In this case report, we present a young female patient of pheochromocytoma with microangiopathic hemolytic anemia.

Case Presentation

A 26-year-old single female patient presented to our hospital with complaints of nausea and vomiting for past 2-3 months. The vomitus was projectile, non-bilious, more pronounced after meals occurring with the frequency of 2-3 episodes every alternate day.

The patient had hypertension for one year. She was taking Nebivolol 5mg OD and amlodipine 5mg/valsartan 80mg OD, however, her hypertension remained uncontrolled despite this treatment.

On admission in August 2025, her observations were as: Blood pressure 170/90mmHg, heart rate 90 beats per minute, afebrile, and had an oxygen saturation of 98% on room air. The physical examination indicated pallor, regular heartrate with no murmurs or additional sounds. The abdominal examination was unremarkable, and no edema or ecchymosis was noted in the lower limbs.

Laboratory investigations were carried out including Complete Blood Count which revealed significant anemia (hemoglobin level of 6.9 g/dl), thrombocytopenia (platelet count 130,000/mm3) and leukocytosis (white blood count 14,710/mm3). Urine routine examination showed hematuria and proteinuria (1+, 1+ respectively), raised serum lactate (45mg/dl), normal serum Procalcitonin (0.43mg/dl) levels. Other investigations were as: Iron 66ug/dl, TIBC 467ug/dl, reduced TSATS 14 %, raised LDH level (562), D Dimers 917, Fibrinogen Level 235.

Keeping in view of her low hemoglobin, another complete blood count with peripheral smear, RBC folate, vitamin B12, direct and indirect coombs test were sent along with C- reactive protein.

A consistent drop in Hemoglobin was noted, her HB dropped to 5.9g/dl with low vitamin B12 and normal RBC folate levels. However, Peripheral blood smear showed the presence of hypochromia (++), shistocytes (+), anisopoikilocytosis (+) and Microcytes (+) in addition to thrombocytopenia, all pointing towards microangiopathic hemolytic anemia (MAHA).

The CRP was mildly raised; Liver function tests were normal along with normal C3, C4 and ENA profile. Direct Coombs test was negative which excluded autoimmune hemolytic anemia.

Her Antinuclear antibody levels (ANA) were borderline positive (1:80) with deranged renal functions (creatinine 3.35mg/dl, urea 60mg/dl, e GFR 18ml/min) along with hyponatremia Na 123mmol/L and hyperuricemia 10.1 mg/dl. On further testing low aldosterone level 90.6pmol/L (195-832), high Renin level 221mIU/L (4.2-45.6), low Aldosterone / Renin 0.40 and normal serum cortisol 12.3ug/dl (6.2 -19.4) were noted.

Table 1: *Laboratory investigations of the patient*

Investigation	Result	Reference Range
Hemoglobin	5.9 g/dL	12–16 g/dL
Platelet Count	130,000 /mm³	150,000–450,000 /mm³
Total Leukocyte Count	14,710 /mm³	4,000–11,000 /mm³
Lactate Dehydrogenase (LDH)	562 U/L	140–280 U/L
D-Dimer	917 ng/mL	<500 ng/mL
Serum Creatinine	3.35 mg/dL	0.6–1.2 mg/dL
Egfr	18 mL/min	>90 mL/min
Sodium	123 mmol/L	135–145 mmol/L
Plasma Renin	221 mIU/L	4.2–45.6 mIU/L
Urinary VMA (24-hour)	35.2 mg/24 h	<13.6 mg/24 h

Given the context of her low hemoglobin, she was transfused with 2 Packed Cell Volume, and in view of raised white blood cell count accompanied with persistent nausea and vomiting, the primary physician suspected sepsis, therefore she was started on Meropenem 500mg BD as an empirical therapy. In view of acute kidney injury (AKI), ARBs were stopped and Ultrasound abdomen & pelvis was suggested. Ultrasound showed two well-defined rounded isoechoic mass lesions at the right suprarenal position.

Lesions showed peripheral vascularity; however, no significant internal vascularity was noted. On suspicion of pheochromocytoma, 24-hour Urinary Vanillylmandelic Acid (VMA) test was sent which came out positive (35.2mg/24 hour).

Keeping in view of ultrasound findings and positive VMA, MRI and Renal Doppler scan was done. Renal Doppler was unremarkable showing Average Resistive index of right intersegmental renal arteries (0.62) and left intersegmental renal arteries (0.58).

MRI scan confirmed Lobulated heterogeneous mass lesion in the region of right adrenal gland, approximately measures 5.5 x 5.2 cm and a well-defined rounded heterogeneous lesion in the region of left adrenal gland, approximately measures 3.5 x 2.3 cm.The mass was compressing the upper pole of right kidney and slightly displacing it inferiorly (Figure 1).

On basis of these findings, a clinical diagnosis of bilateral pheochromocytoma complicated with MAHA and TMA was made.

She was managed symptomatically with primary focus on controlling hypertension, which is being effectively managed by Alpha blocker (Doxazosin 4mg) od and beta blocker (Nebivolo 2.5mg) od and was referred for surgical management. However, the patient did not want to proceed for sugery thus histological confirmation could not be made.

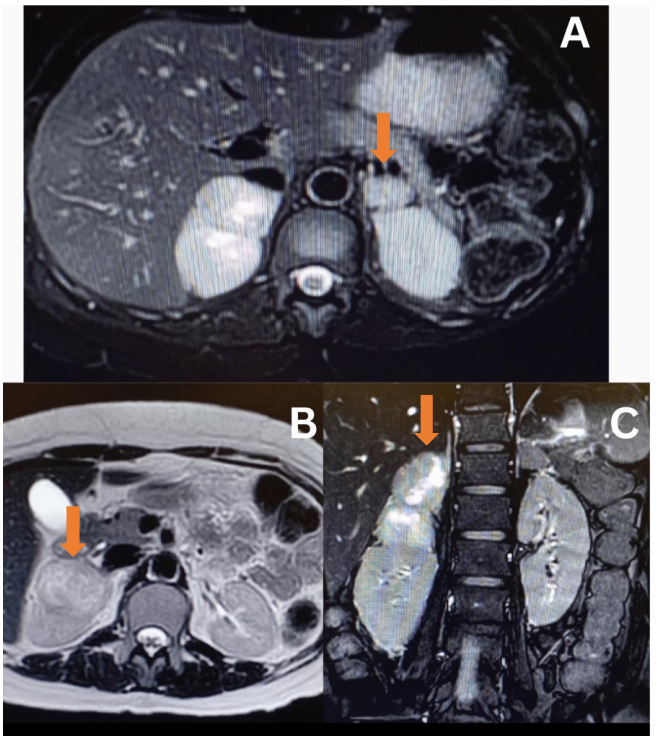

Figure 1: *Magnetic resonance imaging of the abdomen demonstrating a well-defined adrenal mass. (A) Axial T2-weighted image showing lobulated heterogeneous mass lesion in the region of right adrenal gland, approximately measures 5.5 x 5.2 cm (arrow). (B) Axial image showing heterogeneous lesion in the region of left adrenal gland, approximately measures 3.5 x 2.3 cm. (C) Coronal T2-weighted image confirming the size and anatomical extent of the adrenal mass (arrow).*

Discussion

The nationwide incidence data of pheochromocytoma is exceedingly rare with around 27 cases reported in literature in past two decades.[9] The peak incidence of PCC is reported in fourth to fifth decade of life with predominance in female.[6]

Clinically, pheochromocytoma manifests as systemic arterial hypertension and paroxysms (headache, palpitation and sweating) due to stimulation of adrenergic receptor from catecholamine release.[10] In rare instances, it may present as pheochromocytoma crisis (PCC) – which is characterized by hemodynamic instability and end-organ damage or multi-organ dysfunction.[11] PCC is further characterized into type A involving limited manifestation without hypotension, and type B represents more severe form associated with hypotension and end organ damage.[11] The current case aligns with case report with type A PCC, where patient developed renal (Acute kidney injury) and vascular dysfunction (Microangiopathic hemolytic anemia).

The pathophysiology of these complications is directly linked to action of catecholamines. The stimulation of alpha-adrenergic receptors leads to arterial vasoconstriction leading to sustained hypertension and reduced intravascular volume.[12] While the renal injury is attributed to hypertension driven intimal thickening and glomerulosclerosis.[7] In the present case, AKI was attributed primarily to intravascular volume depletion and vasoconstriction. The possibility of renal vein thrombosis was ruled out on doppler scan evaluation.

The uncontrolled hypertension in patients can also result in endothelial injury, damage to red blood cell and platelets subsequently leading to development of Microangiopathic hemolytic anemia (MAHA). MAHA is characterized by elevated lactate dehydrogenase (LDH), increased reticulocyte count, and schistocytes on peripheral smear.[7] All parameters supportive of MAHA were identified in this case except for haptoglobin levels, which were not assessed.

The biochemical gold standard to establish the diagnosis of pheochromocytoma includes measurement of blood and urine metanephrine (MN).[10] while the measurement of 24 hour urinary metanephines was predominant test used prior 2018.[6] Plasma free metanephrines now offer the highest sensitivity (99%).[10] In this patient urinary vanillymandelic acid (VMA) levels were elevated, representing the functional nature of pheochromocytoma. This finding parallels the study Raja et a where 52 out of 53 patients have elevated urinary metanephrines.[13] However, the absence of metanephrine measurements may limit further biochemical confirmation.

Interestingly, this patient exhibited bilateral involvement of adrenal glands which is rare. Raja et al. reported bilateral disease in only 5 out of 52 patients.[13] While Lu et al. observed no bilateral involvement in cohort of 19 patients.[4] In similar study tumor size ranged from 2.5 to 12 cm, which is similar to our case where both left and right sided tumor ranged between 2.3 to 5.5 cm. Radiologically, MRI demonstrated the presence of heterogenous mass, a feature consistent with prior series of 52 patients where 65% patients pheochromocytoma appeared solid and heterogenous on MRI.[13]

In this patient management primary focused on managing hypertension and advised for adrenalectomy. First line pharmacological therapy involves Alpha-blockade either alone or combined with calcium channel blockage or magnesium sulfate. The beta-blockers are avoided prior and, after the use of alpha-blockage to prevent unopposed alpha-adrenergic activity or intravascular depletion and hypotension.[12] However, beta-blockers were effective in reducing the heart rate in 71% of patients in a study by Lu et al.[4] Furthermore, the definitive treatment of functional pheochromocytoma remains surgical excision with better outcomes seen with laparoscopic adrenalectomy as compared to open adrenalectomy.

This case has certain limitations. First, the diagnosis of bilateral pheochromocytoma was based on clinical, biochemical, and radiological findings; however, histopathological confirmation could not be obtained because the patient declined the surgical intervention. Second, the genetic screening for hereditary tumor predisposition syndrome was not performed, limiting the assessment of a potential etiology.

Conclusion

The case highlights a rare presentation of bilateral pheochromocytoma in a young female, complicated by microangiopathic hemolytic anemia (MAHA) and acute kidney injury (AKI). The diagnosis was established through characteristic clinical features, elevated urinary vanillymandelic acid levels, and radiological evidence of bilateral masses. The combination of hematologic abnormalities, renal dysfunction, and hypertensive symptoms underscores the importance of considering pheochromocytoma in the differential diagnosis in patients with multisystem involvement. This case contributes to the limited literature on pheochromocytoma-associated thrombotic microangiopathy and highlight as uncommon but critical diagnostic entity.

Patient Consent and Permission: Informed, written consent was obtained from the patient for the publication of this case report, including images.

Conflict of Interest None

Funding Source None

Authors' Contribution

FI: Conception.

HZ, AA: Design of the work.

MAR, HA: Data acquisition, analysis, or interpretation.

HZ, AA, MAR: Draft the work.

FI, HZ: Review critically for important intellectual content.

All authors approve the version to be published.

All authors agree to be accountable for all aspects of the work.

References

1. Junejo SZ, Tuli S, Heimann DM, Sachmechi I, Reich D. A case report of cystic pheochromocytoma. Am J Case Rep. 2017; doi: 10.12659/ajcr.905042
2. Rey Chaves CE, Ayala D, García G, Conde Monroy D, Sabogal Olarte JC. Retroperitoneal pheochromocytoma: unsual presentation and atypical location. Int J Surg Case Rep. 2021;doi: 10.1016/j.ijscr.2021.106248
3. Karasek D, Shah U, Frysak Z, Stratakis C, Pacak K. An update on the genetics of pheochromocytoma. J Hum Hypertens. 2013;27(3):141-7.
4. Lu C, Naushad AA, R MP, Kalra P, Selvan C, Y P G, et al. Pheochromocytoma: Clinical Experience From a Single Tertiary Care Center in India. Cureus. 2023;15(7):e41671.
5. Boro H, Sharma H, Mittal D, Kaswan RS, Saran DP, Nagar N, et al. Pheochromocytoma, the great masquerader, presenting as reversible cardiomyopathy: primum non nocere. Acta Endocrinol (Buchar). 2023;19(3):370-5.
6. Sohail S, Shafiq W, Raza SA, Zahid A, Mir K, Azmat U. Clinical characteristics and outcome of patients with pheochromocytoma: a single center tertiary care experience. Cureus. 2020;12(5):e7990.
7. Sharma N, Ravi D, Khan M, Sravanthi MV, Aloysius MM. Microangiopathic hemolytic anemia and fulminant renal failure: a rare manifestation of pheochromocytoma. Case Rep Endocrinol. 2019;doi: 10.1155/2019/2397638
8. Heih OQ, Manasra MR, Salah ZF, Hroub MM, Arafat H, Abu Aqeel BI, et al. Microangiopathic hemolytic anemia as paraneoplastic syndrome secondary to pheochromocytoma: a rare case report. Oxf Med Case Reports. 2025;2025(3):omaf034.
9. Ch I Z, Ishtiaq S, Aslam H, Khan Y Y A, Pheochromocytoma with neurofibromatosis type 1 JAMDC, 2023;5(4): 250-4.
10. Lima JV Júnior, Kater CE. The Pheochromocytoma /Paraganglioma syndrome: an overview on mechanisms, diagnosis and management. Int Braz J Urol. 2023;49(3):307-19.

11. Bartikoski SR, Reschke DJ. Pheochromocytoma Crisis in the Emergency Department. Cureus. 2021;13(3):e13683.
12. Thomas MR, Scully M. How I treat microangiopathic hemolytic anemia in patients with cancer. Blood. 2021;137(10):1310-7.
13. Raja A, Leung K, Stamm M, Girgis S, Low G. Multimodality imaging findings of pheochromocytoma with associated clinical and biochemical features in 53 patients with histologically confirmed tumors. AJR Am J Roentgenol. 2013;201(4):825-33.